

Prosopagnosia: neuro-functional basis of face recognition impairment

Contributed by Bruno Rossion (text updated, July 2015)¹

<http://face-categorization-lab.webnode.com/research/acquired-prosopagnosia/>

See the recent review on this topic:

Rossion, B. (2014). Understanding face perception by means of prosopagnosia and neuroimaging. *Frontiers in Bioscience (Elite Ed.)*; 6-308-317

Available here: http://files.face-categorization-lab.webnode.com/200001662-e13c4e3b61/Bruno_FrontiersBScience2014.pdf

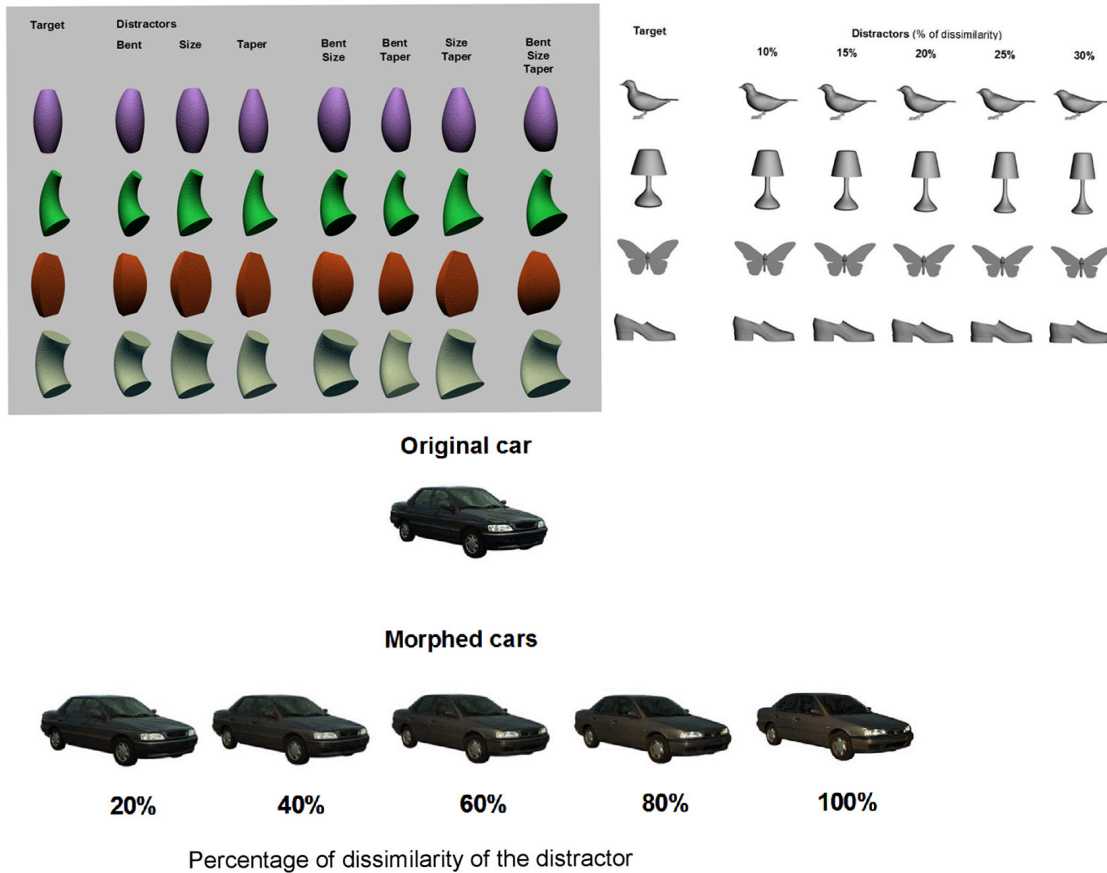
Following brain damage (trauma, stroke ...), some people may present with great difficulties at recognizing familiar faces, and encode new faces in memory. This visual recognition impairment does not appear to be due to sensory visual defects or intellectual disorders. Recognition of other people through other modalities, the voice for instance, is preserved. This condition was termed **prosopagnosia** by Bodamer (1947) and first described by Wigan in 1844, and then Quaglino & Borelli in 1867 (paper translated by Ellis & Florence, 1990).

Cases of acquired prosopagnosia with preserved visual functions are extremely rare. In particular, most cases of prosopagnosia following brain damage also present with impairments at object recognition. Thus, prosopagnosia is generally observed in the context of **visual agnosia**. For instance, we reported a case of acquired prosopagnosia in the context of a visual agnosia: **NS** (Delvenne et al., 2004). Similarly, the visual agnostic patients *LH* (Levine & Calvanio, 1989), *HJA* (Riddoch & Humphreys, 1987), *SM*, *RN*, *CR* (e.g., Behrmann & Kimchi, 2003) have been investigated in several studies for their face recognition impairment (e.g., *LH*: Farah et al., 1995; *HJA*: Boutsen & Humphreys, 2002; *SM*, *CR*: Gauthier et al., 1999), which is often severe.

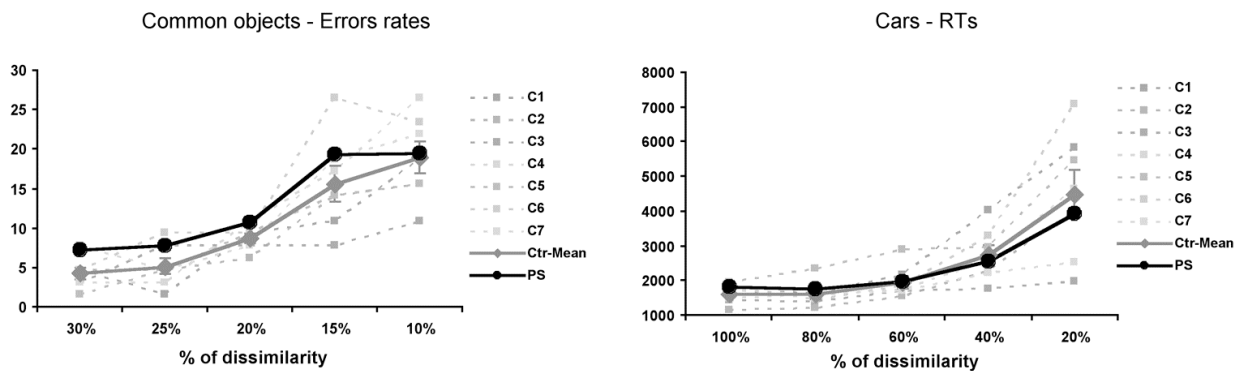
Because of that, and more generally because it is difficult to believe that *only* face recognition could be impaired following brain damage, the question of whether prosopagnosia can be 'pure' (without object recognition impairments) is still debated. However, there are a few patients who do not complain of object recognition difficulties at all (unlike the cases mentioned above, who are well aware of their difficulties). More importantly, these patients perform like normal observers at object recognition tasks. We provide a summary of such cases (Busigny et al., 2010).

In that paper, we also show that acquired prosopagnosia in such cases cannot be simply explained by a difficulty at recognizing and discriminating visually similar items (still a popular account of prosopagnosia). Here, **PS**, a well-known case of prosopagnosia, can discriminate visually similar items just as well and as fast as normal controls: simple geometric shapes, morphed pictures of common objects, and morphed photographs of cars, as illustrated above.

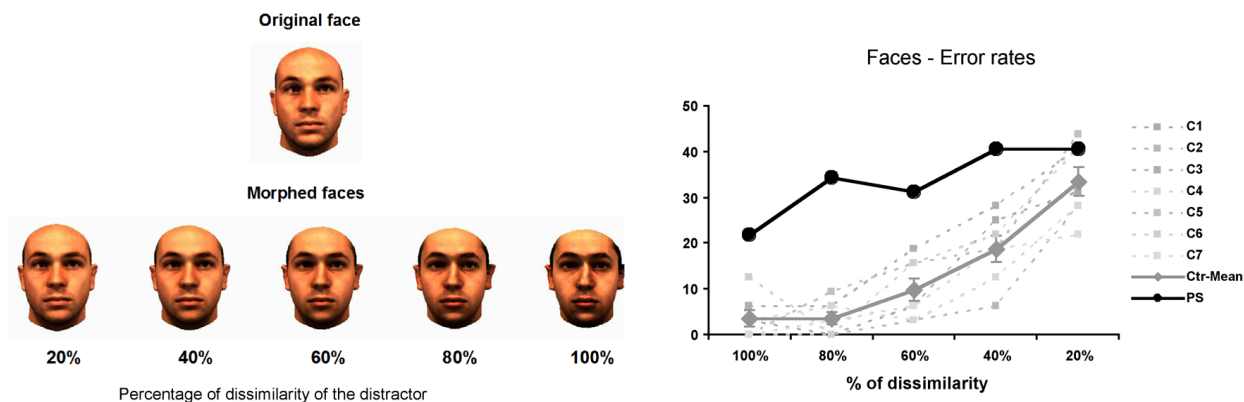
¹ Author's note: this text summarizes the research and research program pursued in the author's laboratory (face categorization lab) at the University of Louvain. It is not meant to provide a review of (acquired) prosopagnosia, and the text also reflects the author's personal view on theoretical and methodological issues concerning this topic.



In that paper, we also show that acquired prosopagnosia in such cases cannot be simply explained by a difficulty at recognizing and discriminating visually similar items (still a popular account of prosopagnosia). Here, **PS**, a well-known case of prosopagnosia, can discriminate visually similar items just as well and as fast as normal controls: simple geometric shapes, morphed pictures of common objects, and morphed photographs of cars, as illustrated above.



However, if the items are **faces**, impairments are found even at the easiest levels of discrimination (individual faces “easy” to distinguish).



From Busigny et al., 2010, *Neuropsychologia*, 48, 2051-2067.

Recently, we also reported an extensive investigation (24 experiments) of another case of acquired prosopagnosia, GG, who also presents with normal object recognition and fine-grained discrimination of non-face objects (but not faces) (Busigny et al., 2010, *Neuropsychologia*, 48, 4057-4092).

Neuropsychologia 48 (2010) 4057–4092



Contents lists available at ScienceDirect

Neuropsychologia

journal homepage: www.elsevier.com/locate/neuropsychologia



Holistic perception of the individual face is specific and necessary: Evidence from an extensive case study of acquired prosopagnosia

Thomas Busigny^{a,*}, Sven Joubert^b, Olivier Felician^c, Mathieu Ceccaldi^c, Bruno Rossion^a

^a Université Catholique de Louvain, Louvain-la-Neuve, Belgium

^b Département de Psychologie, Université de Montréal & Centre de Recherche Institut Universitaire de Gériatrie de Montréal, Canada

^c Service de Neurologie et de Neuropsychologie, AP-HM Timone, & Laboratoire Epilepsie et Cognition, INSERM U 751, Université de la Méditerranée, Marseille, France

ARTICLE INFO

Article history:

Received 17 March 2010

Received in revised form 5 August 2010

Accepted 16 September 2010

Available online 25 September 2010

Keywords:

Acquired prosopagnosia

Specificity

Face processing

Holistic perception

Right hemisphere

ABSTRACT

We present an extensive investigation (24 experiments) of a new case of prosopagnosia following right unilateral damage, GG, with the aim of addressing two classical issues: (1) Can a visual recognition impairment truly be specific to faces? (2) What is the nature of acquired prosopagnosia? We show that GG recognizes nonface objects perfectly and quickly, even when it requires fine-grained analysis to individualize these objects. He is also capable of perceiving objects and faces as integrated wholes, as indicated by normal Navon effect, 3D-figures perception and perception of Mooney and Arcimboldo face stimuli. However, the patient could not perceive individual faces holistically, showing no inversion, composite, or whole-part advantage effects for faces. We conclude that an occipito-temporal right hemisphere lesion may lead to a specific impairment of holistic perception of individual items, a function that appears critical for normal face recognition but not for object recognition.

© 2010 Elsevier Ltd. All rights reserved.

Such studies provide clear evidence that acquired prosopagnosia can be ‘pure’ in some rare cases. Thus, there are certain processes in the human brain that are necessary for face recognition but not for object recognition.

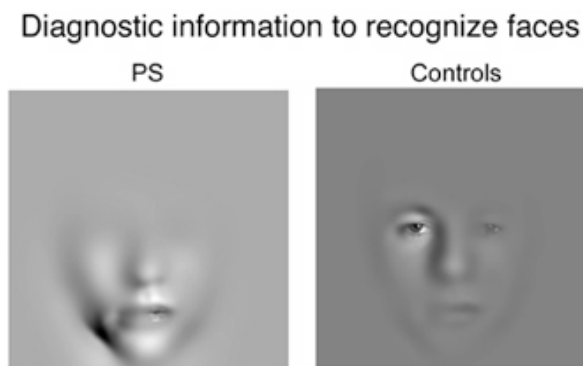
Besides this issue of specificity, studying cases of prosopagnosia can be particularly interesting, for two reasons at least:

1. The kind of visual cues that they still can, or cannot, extract and remember from faces may help us understanding better how normal people recognize faces (what kind of information processes are important) (see e.g., [Caldara et al., 2005](#); [Van Belle et al., 2010](#)).
2. Such studies can help us understanding better the location and the critical role(s) of the brain areas involved in normal face recognition (see e.g., [Rossion et al., 2003](#); [Schiltz et al., 2006](#); [Rossion et al., 2011](#)).

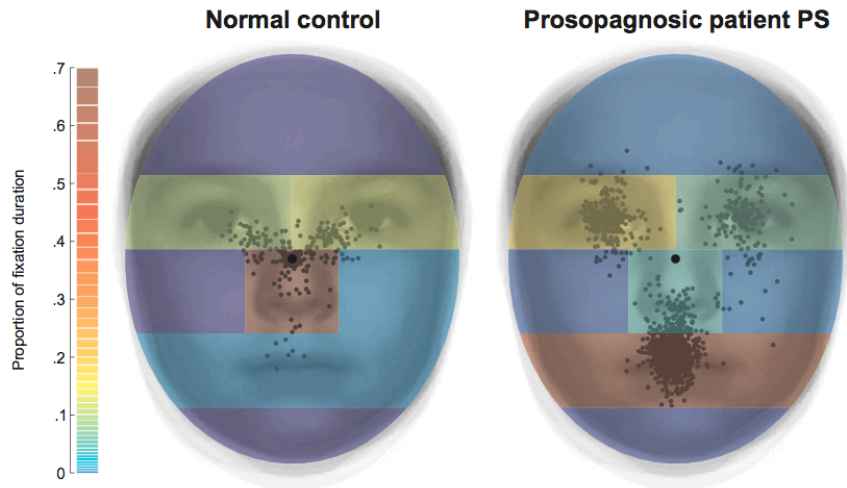
Because the patients are extremely rare and all have different associated impairments, we advocate the detailed investigations of *single-cases* of acquired prosopagnosia rather than group studies.

For instance, since 2000 we have been studying a fascinating case of prosopagnosia, **PS**, who sustained brain damage in 1992 at the age of 41. She has recovered all neuropsychological functions but presents with a severe prosopagnosia. Unlike the majority of cases of prosopagnosia, PS recognizes objects without any difficulties (accurate and fast), including living things, and she never complains of any object recognition difficulties. She can even discriminate visually similar objects at the individual level (e.g. discriminating two pictures of cars, or birds) like normal people, at a normal speed (see above, and [Busigny et al., 2010](#)). Unlike many cases of prosopagnosia, she is not achromatopsic either, nor does she suffer from topographical agnosia. She has a small left paracentral scotoma and a low but normal range color vision ([Sorger et al., 2007](#)), and these slight deficits cannot account for her prosopagnosia.

By presenting PS with small pieces of information sampled randomly on face pictures during hundreds of trials ('Bubbles', Gosselin & Schyns, 2001) and measuring her performance, we showed that she suffers from a deficit at extracting information at the level of the eyes of the faces, and mostly relied on the mouth ([Caldara et al., 2005](#)).



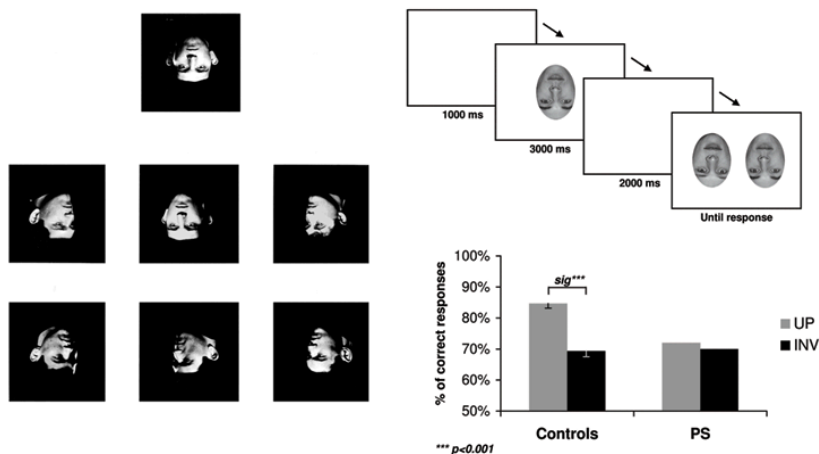
In another study, eye movement recordings showed that **PS fixates mainly the mouth during identification of personally familiar faces**. Moreover, the location of eye gaze fixation indicates a feature-by-feature strategy, with fixations landing exactly on each feature. In contrast, normal observers fixate in the center of the face slightly below the eyes ([Orban de Xivry et al., 2008](#)).



Note that the two studies do not provide the same kind of information, and are complementary: while response classification determines which areas of the face are diagnostic for recognizing faces, eye movement recordings tell us where people look. Interestingly, it is not the same for normal observers: their eyes are highly diagnostic, but the optimal area of fixation seems to be located in between features. For PS, the two converge: she seems to have to fixate exactly on the feature that she wants to use to recognize the face.

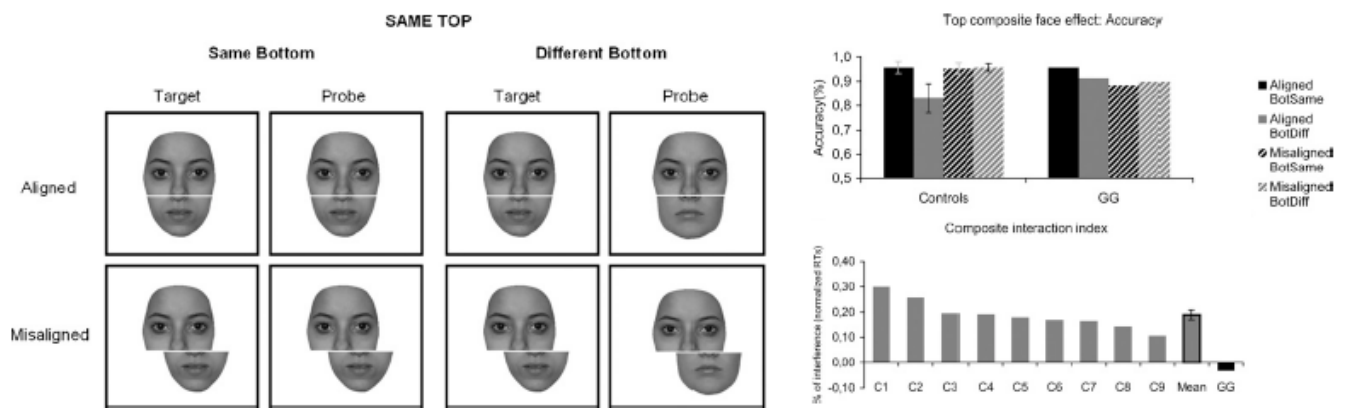
It seems that this loss of ability to extract diagnostic information at the level of the top part of the face, in particular the eye region, is a **dominant aspect of prosopagnosia**. Studies of cases of acquired prosopagnosia by other researchers using unfamiliar face matching tasks (Bukach et al., 2006; 2008; see also [Rossion et al., 2009](#) for converging evidence in PS using unfamiliar face matching), as well as a study on another case of prosopagnosia studied in our laboratory (GG, [Busigny et al., 2010b](#)), support this view.

We believe that the reason why patients with prosopagnosia (with different lesions) show the same behavior, relying less on the eyes of faces than normal observers, is because of their *inability to perceive faces holistically*. This inability to perceive individual faces holistically can be shown by the **absence** (or reduction) of **face inversion effect** ([Busigny & Rossion, 2010](#)).



In this study for instance, we showed in five experiments that PS does not present with a decrease of performance when matching inverted faces as compared to upright faces (Busigny & Rossion, 2010). Importantly, we used tasks that she always performed above chance-level at upright orientation. Note that with PS or other cases of acquired prosopagnosia (NS, Delvenne et al., 2004; GG, Busigny et al., 2010b), we never observed a superiority of performance for inverted faces (Farah et al., 2005), a rare observation which we believe to be due to low-level visual impairments (superior visual field defects, see Busigny & Rossion, 2010).

This inability to perceive individual faces holistically is also shown by abnormal composite and whole-part effects (Ramon et al., 2010; see also Ramon & Rossion, 2010; Busigny et al., 2010b): when they have to match facial parts (the eyes, or half of the face), prosopagnosic patients' performance is not affected by the presence and identity of the other face parts.



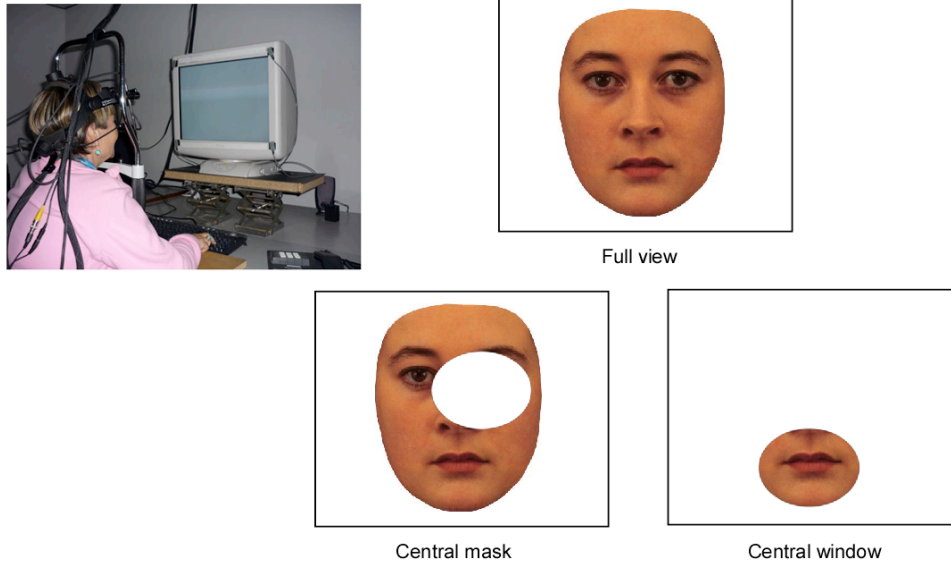
Why would this abnormal holistic processing be related to the reduced diagnosticity (and fixation) of the region of the eyes in prosopagnosia?

We have no reason to believe that this behavior is related to a form of autistic behavior, in which the patient would avoid looking at the eyes. In fact, they do look at the eyes (in normal life or even in experimental tasks), but this area seems to have lost its diagnosticity to recognize faces. There is no reason to believe either that this behavior would be due to specific low-level properties of the eyes vs. the mouth for instance, as this pattern can be observed in different patients, whose low-level vision is largely preserved (or intact in some cases). Moreover, the lack of diagnosticity of the eyes can be observed across multiple spatial scales (Caldara et al., 2005).

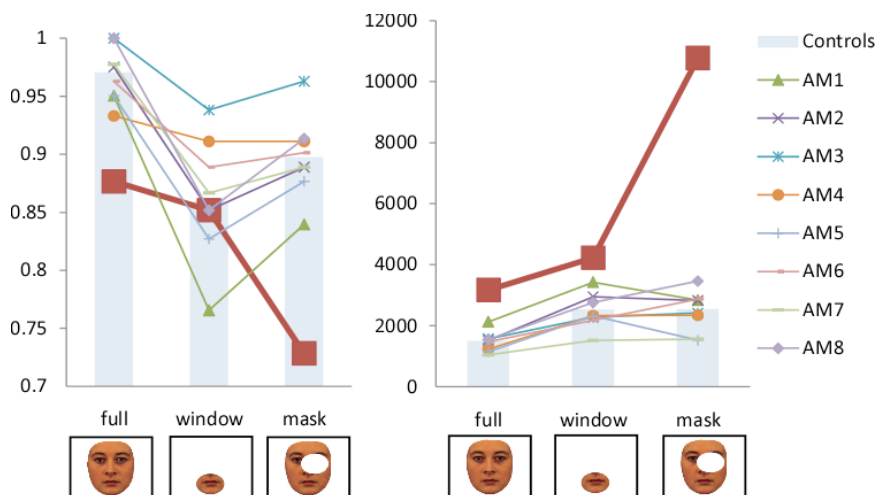
Rather, our view is the following. The region of the eyes of the face contains a lot of diagnostic information to individualize faces. However, this information is distributed among several elements (2 eyes, 2 eyebrows, ...) and their relations (relative distances, such as interocular distance), all potentially diagnostic of facial identity. If one is able to extract this area as a whole template, it can be extremely diagnostic of facial identity, allowing rapid individualization of the face. However, in itself, each element carries little information. Hence, the diagnosticity of this area would depend heavily on the integrity of holistic processing (Caldara et al., 2005; Orban de Xivry et al., 2008; Ramon & Rossion, 2010). If holistic processing is disrupted, a good strategy is to rely the mouth, a single element relatively well

isolated on the lower part of the face, and potentially quite diagnostic of identity by itself (as compared to one eye for instance).

With eye movements and behavioral measures, our most recent and original work rely on a **gaze contingency** method to show directly that acquired prosopagnosia is related to a feature-by-feature analysis of individual faces (Van Belle et al., 2010). With gaze-contingency, we tested **PS** in a delayed matching task in 3 conditions: faces in full view, faces limited to a central window around **PS**' fixation spot (**window condition**) and faces with the area around the fixation spot covered by a mask (**mask condition**).



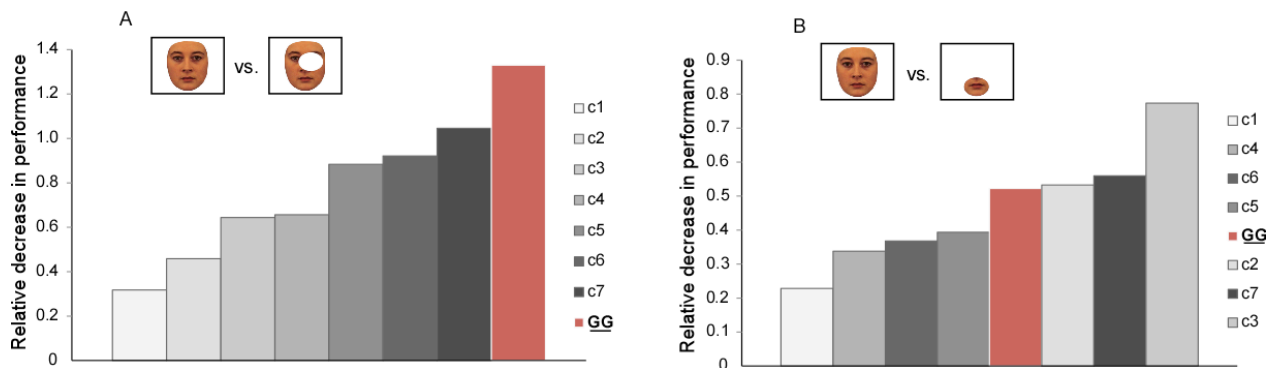
Very interestingly, **PS** had a pattern of response which was opposite to normal observers: she did not show a major decrease of performance in the window condition, but was largely impaired and slow (almost 12 seconds by trial !) in the mask condition. It is as if she was almost **unimpaired** when forced to use one feature at a time (the feature that she could choose to fixate) in the **window** condition. And, at the same time, it seems she **could hardly** match the individual faces if she was prevented from applying her feature-by-feature strategy (in the **mask** condition).



These findings with gaze-contingency shed new lights on the understanding of the nature of acquired prosopagnosia (and thus on what is critical in our expert ability to individualize faces): **these people cannot perceive an individual face as a whole**. Whereas normal observers can fixate on one eye and still extract diagnostic information from the mouth and other parts of the face, patients with prosopagnosia *have to* fixate the mouth, or the part that they want to use to individualize the face.

Importantly, this impairment is not due to a low-level visual defect (peripheral vision) (see [Van Belle et al., 2010](#)). Moreover, even holistic perception of nonface patterns (Navon hierarchical letters, see [Busigny & Rossion, 2011](#)) or holistic perception of faces just to detect these faces (face detection, Mooney or Arcimboldo faces) is preserved ([Busigny et al., 2010b](#); [Rossion et al., 2011](#)). It is only when she has to individualize a face that PS shows a **reduced perceptual field**, relying on a feature-by-feature strategy and being unable not to do that.

Later on, we found that another case of prosopagnosia following a different pattern of brain damage, the case of **GG** reported by [Busigny et al., 2010b](#), also showed the same profile of response: relative to normal controls, he was more impaired at recognizing faces in the mask condition than in the window condition ([Van Belle et al., 2011](#)).



GG also showed the same pattern of eye gaze fixations as described for PS above (fixations on the mouth or eye, while normal observers fixate in the centre of the face), and so did the patient LR, yet another case of acquired prosopagnosia ([Busigny et al., 2014](#)).

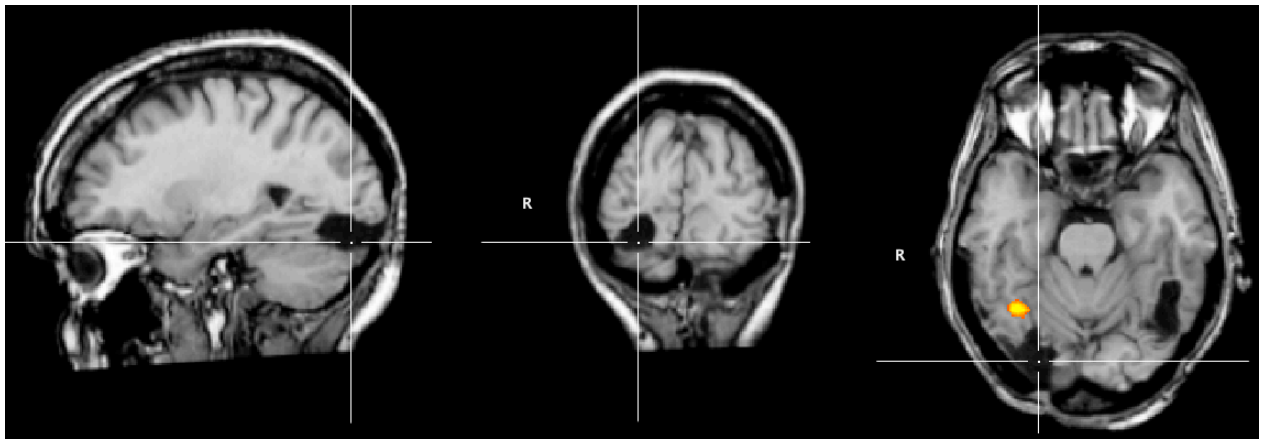
Altogether what these studies suggest is that faces form a special class of visual stimuli for the typical adult human brain: we are able to quickly individualize a face, and thus discriminate individual faces, based on a holistic percept. What makes faces special when it comes to facial identity is not that they are processed holistically – it is the case for other objects also – *or* that we can individualize them despite their high visual similarity: **it's the necessary combination of the two factors**. That is, we can perceive a face holistically, even at a degree of resolution that is sufficient to individualize it. In contrast, when nonface objects have to be individualized, we appear to rely on specific local features or a single property of the object.

Remarkably, this impairment in **holistic individualization of the face** is observed in several cases of prosopagnosia with different brain damage. Consider for instance the different lesions of PS and GG, who show little overlap with each other ([Van Belle et al., 2011](#)).

Interestingly, the studies performed with the prosopagnosic patients described in our papers suggest that this ability is very fragile, and depends on a network of areas in the right ventral occipito-temporal cortex. In order to understand this aspect better, we should turn to studies performed with cases of prosopagnosia at the neuro-functional level...

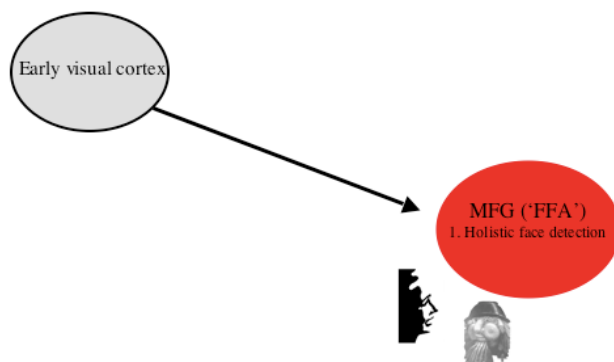
At the neural level, we have performed (f)MRI studies of **PS** mainly, and learned a number of things.

First, much to our surprise (initially), we found that **PS** has a right middle fusiform area responding much more to faces than other objects. Hence, **she presents with a right FFA** (Rossion et al., 2003).

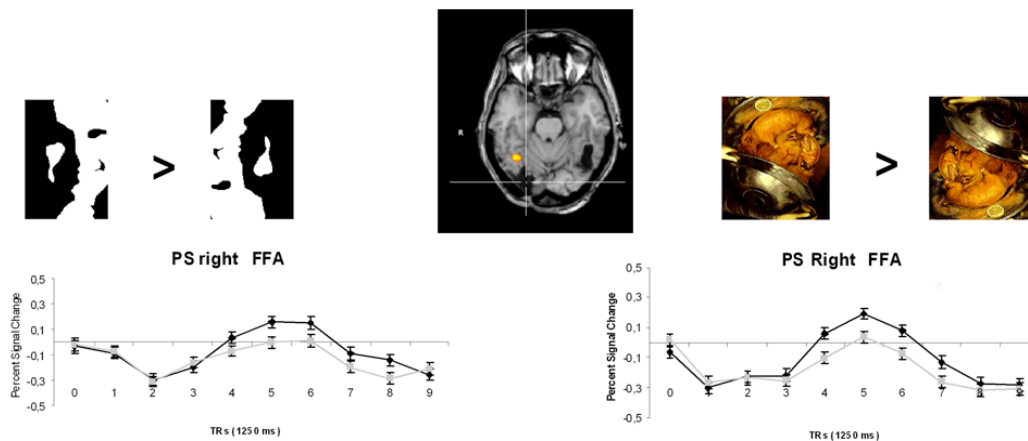


In fact, her main lesion in the right hemisphere destroyed part of the inferior occipital cortex, where preferential processing for faces is usually observed in neuroimaging studies of normal subjects ('occipital face area', **OFA**), and which appears to be a region often damaged in cases of prosopagnosia (see Bouvier & Engel, 2006). This observation has been made also with the visual agnostic patient DF, who presents with a bilateral FFA without any OFA (Steeves et al., 2006)

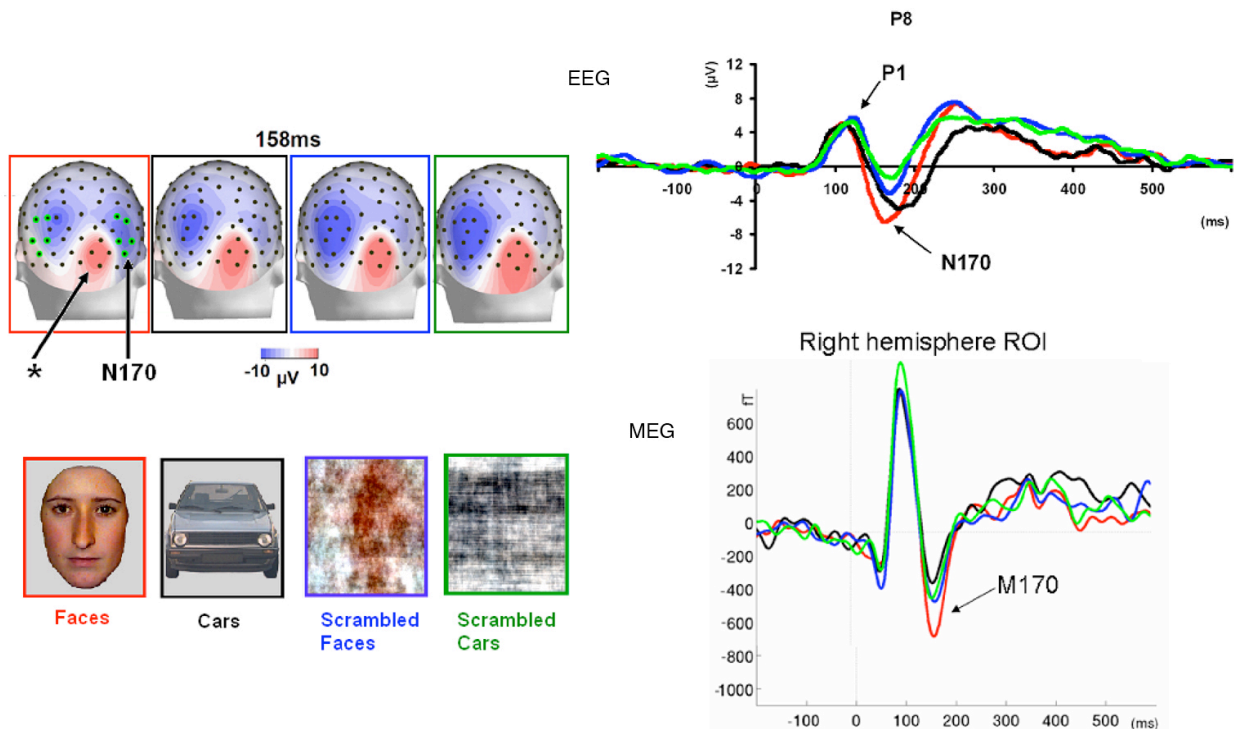
These observations suggest that in the normal brain face-related activity in the middle fusiform gyrus (i.e., the FFA) is not necessarily dependent on inputs from the posteriorly located OFA, as advocated by feedforward hierarchical models of face processing (e.g., Haxby et al., 2000; Ishai, 2008) (see Rossion, 2008, *Neuroimage*, 40, 423-426).



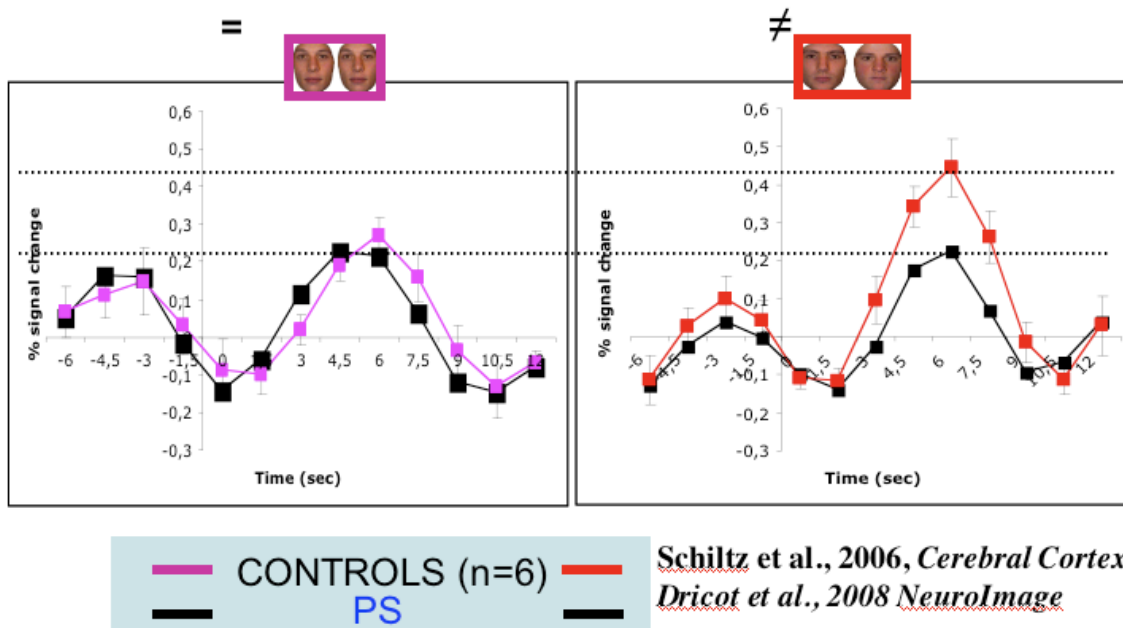
In other words, there must be direct connections from early visual areas to the FFA. Such connections could lead to the initial perception of a visual stimulus as a face. Such a direct pathway would make sense because a face appears to be initially perceived as a global – or holistic – generic representation rather than a collection of facial parts. **PS** is perfectly able to see a face as a face, even when the parts alone are not diagnostic of a face (“Mooney faces”, “Arcimboldo faces”; [Rossion et al., 2011](#)).



How early in time is this face-sensitive response in PS' brain? One may thought that the absence of face-sensitivity in the right occipital cortex would slow down the latency of face-sensitivity for PS. This is not the case: if you record EEG or MEG on PS' scalp, you will observe a N170 face component in the right (but not the left) hemisphere ([Alonso-Prieto et al., 2011](#)).

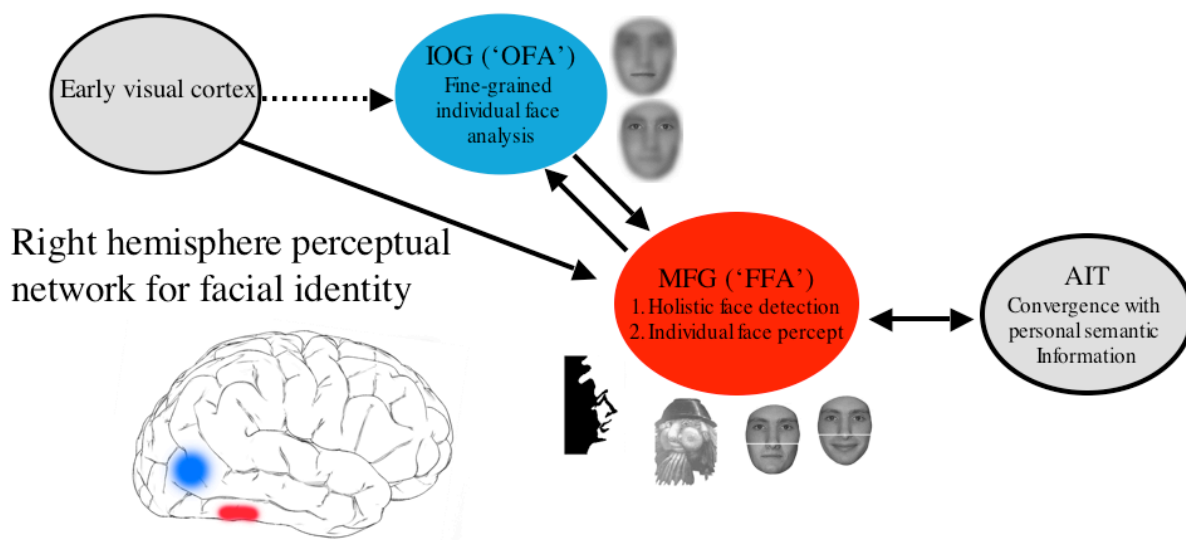


Now, let's come back to fMRI. Even if **PS'** (right) FFA is present, other studies of our group show that **PS'** FFA does not discriminate between individual faces, in line with the behavior of the patient ([Schiltz et al., 2006](#); [Dricot et al., 2008](#)): it shows adaptation when different individual faces are presented.



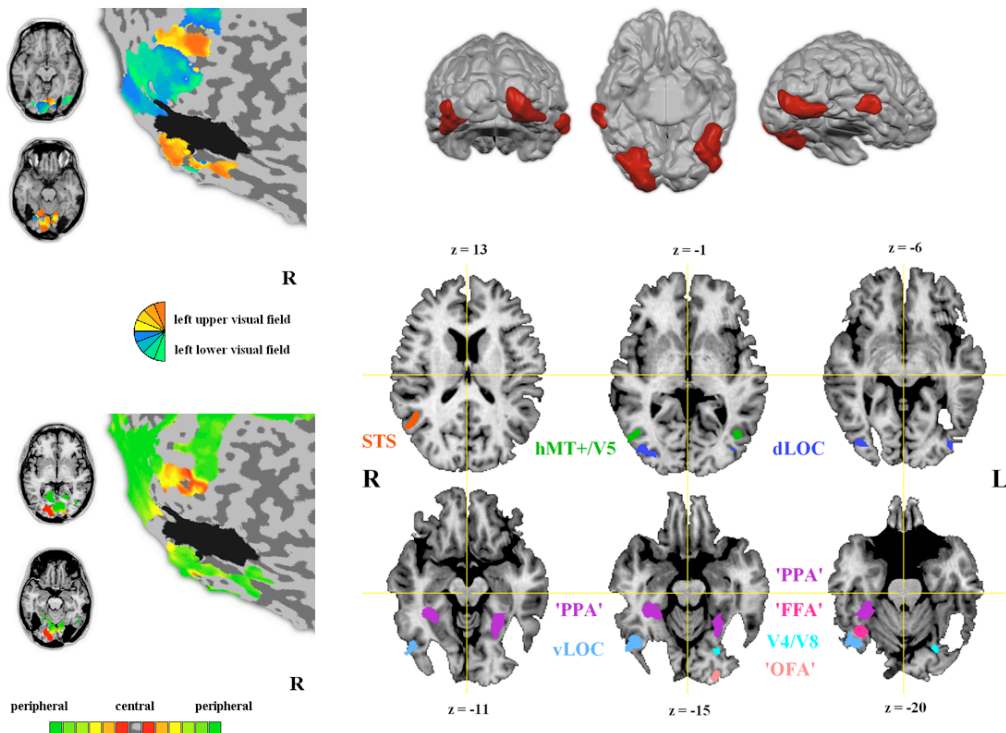
These last findings have also been replicated with the visual agnostic patient **DF** ([Steeves et al., 2009](#)).

They suggest that other areas than the FFA might be important to derive an *individual* representation of a face, such as the OFA, perhaps through reentrant connections.

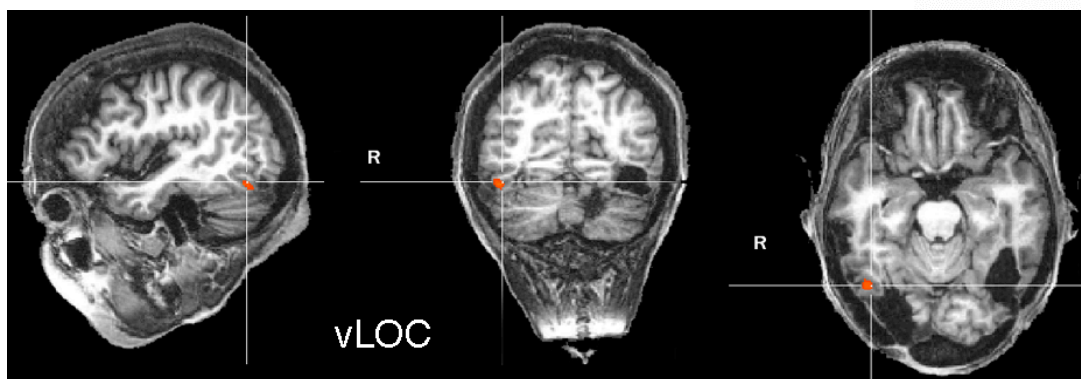
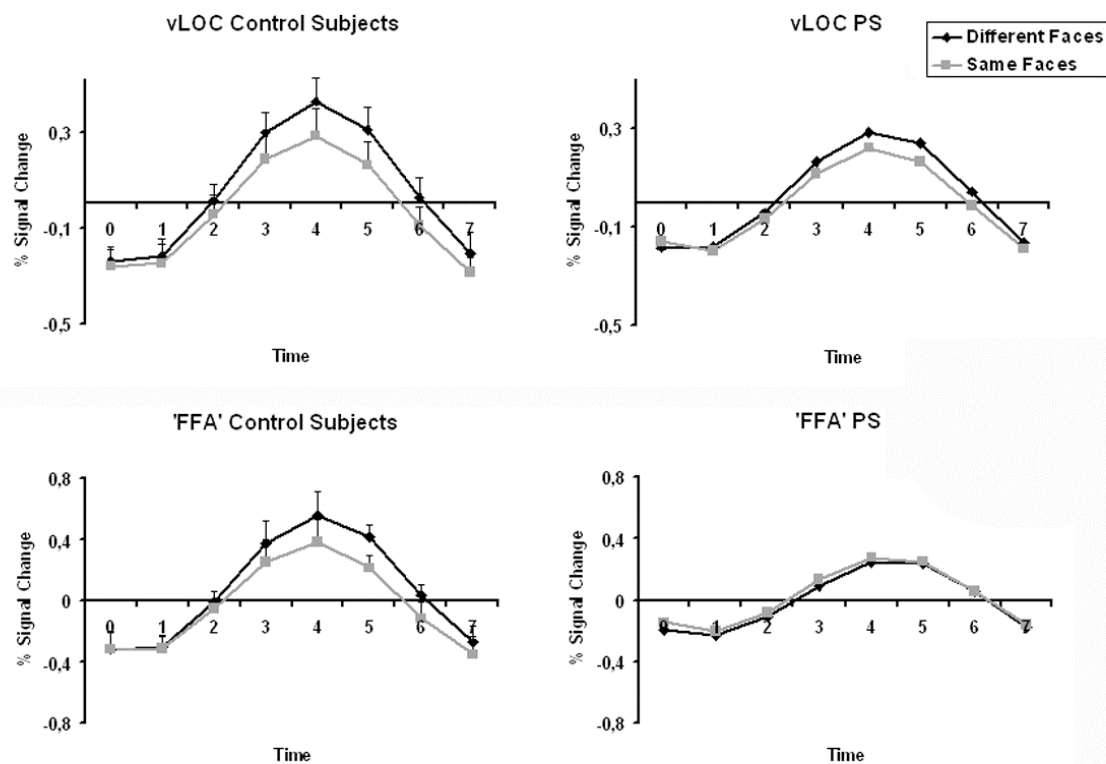


Hence, a region such as the OFA might be involved specifically in face processing *after* the initial face-related activation in the FFA, in order to refine the representation of a face (Rossion, 2008).

Mapping of the visual cortex of the prosopagnosic patient **PS** provides clues about the reasons why **PS'** deficit is specific for that category: while her main lesion in the right hemisphere destroyed part of the inferior occipital cortex, the lesion spared the ventral and dorsal part of the lateral occipital complex (LOC), as well as parahippocampal areas, where recognition of non-face objects may take place (Sorger et al., 2007).



That the ventral section of the LOC in the right hemisphere is structurally and functionally intact is amazing, given the localization of the right hemisphere lesion. Interestingly, while the FFA does not show release from adaptation to individual faces for **PS**, we found such an effect in the vLOC of the patient (Dricot et al., 2008)! The effect was also found for control participants in that study, indicating that it cannot be defined as a specific reorganization for **PS**: individualization of faces in the intact brain is also supported by regions that do not, as a whole, show a larger response to faces than objects.



These observations indicate that individualization of faces for the patient is not based on the face processing system, but on areas that are not optimally (i.e., specifically) tuned to process face stimuli (Dricot et al., 2008).

Eliciting transient prosopagnosia using intracerebral electrical stimulation

To be completed ...

BIBLIOGRAPHY (lab papers on this topic) and main finding(s) of each paper

All papers available as pdfs here:

1	<p>Rossion, B., Caldara, R., Seghier, M., Schuller, A.-M., Lazeyras, M., Mayer, E. (2003). A network of occipito-temporal face-sensitive areas besides the right middle fusiform gyrus is necessary for normal face processing. <i>Brain</i>, 126, 2381-2395.</p> <p><i>First behavioral and neuroimaging study of the case of PS, showing that she presents with a severe and highly specific impairment at face recognition, including individual face matching/discrimination. In fMRI, she presents with a normal (magnitude, size, location) preferential activation for faces in the right middle fusiform gyrus (FFA), despite a lesion of the right inferior occipital cortex and no OFA. This unexpected finding has led us to question the hierarchical view of the neural circuitry of face perception (OFA to FFA). It has been replicated since then in many studies listed above, by other groups of researchers also, and in another case of acquired prosopagnosia.</i></p>
2	<p>Delvenne, J.-F., Seron, X., Coyette, F., Rossion, B.(2004). Evidence for perceptual deficits in associative visual (prosop)agnosia: a single-case study. <i>Neuropsychologia</i>, 42, 597-612.</p> <p><i>Patient NS. A remarkable case of visual agnosia, with lesions sparing the occipital cortex. A series of behavioral experiment shows that despite a classification as a case of associative agnosia, the patient presents with impairments of perceptual nature. Impairment at integrating features into a coherent whole (integrative visual agnosia), no inversion effect</i></p>
3	<p>Caldara, R., Schyns, P., Mayer, E., Smith, M., Gosselin, F., Rossion, B. (2005). Does prosopagnosia take the eyes out from faces? Evidence for a defect in the use of diagnostic facial information in a brain-damaged patient. <i>Journal of Cognitive Neuroscience</i>, 17, 1652-1666.</p> <p><i>Patient PS. First evidence for a defect at extracting diagnostic information from the eyes of faces in acquired prosopagnosia, by means of response classification ('Bubbles'). Like the observation of a preserved right FFA in the patient's brain (Rossion et al., 2003), this was also an unexpected result: we were just interested in defining what kind of information was no longer diagnostic of identity for the prosopagnosic, without a priori.</i></p>
4	<p>Schiltz C, Sorger B, Caldara R, Ahmed F, Mayer E, Goebel R, Rossion B. (2006). Impaired face discrimination in acquired prosopagnosia is associated with abnormal response to individual faces in the right middle fusiform gyrus. <i>Cerebral Cortex</i>, 16, 574-586.</p> <p><i>First evidence that the (right) FFA does not show release from adaptation to individual faces in acquired prosopagnosia (PS). Block design and event-related experiments, multiple sessions. Suggest that the damaged right OFA is necessary to help the FFA individualizing faces.</i></p>
5	<p>Sorger, B., Goebel, R., Schiltz, C., Rossion, B. (2007). Understanding the functional neuroanatomy of prosopagnosia . <i>NeuroImage</i>, 35, 836 - 852.</p> <p><i>A detailed anatomical and functional study of the brain of a rare case of pure prosopagnosia (PS). Localization and extent of lesions, retinotopy, LOC, MT localizers.</i></p>
6	<p>Rossion, B. (2008). Constraining the cortical face network by neuroimaging studies of acquired</p>

	<p>prosopagnosia. <i>NeuroImage</i>, 40, 423-426.</p> <p><i>A brief commentary and summary of our research showing how combining single case studies of prosopagnosia and neuroimaging can greatly inform about the neural basis of face processing</i></p>
7	<p>Dricot, L., Sorger, B., Schiltz, C., Goebel, R., Rossion, B. (2008). The roles of “face” and “non-face” areas during individual face perception: evidence by fMRI adaptation in a brain-damaged prosopagnosic patient. <i>NeuroImage</i>, 40, 318-332.</p> <p><i>Previously, we showed that PS’ right FFA does not show any release from adaptation when different individual faces are presented (Schiltz et al., 2006). This observation is replicated here, but the question is: why does the patient perform better than chance level at individual face discrimination? What are the neural substrates of this performance? We find release to individual face adaptation in the ventral part of the right lateral occipital cortex (vLOC) of PS, spared by the lesion. Hence, she appears to rely on a general visual area to individualize faces rather than on her residual face processing system.</i></p>
8	<p>Orban de Xivry, J.-J., Ramon, M., Lefèvre, P., Rossion, B. (2008). Reduced fixation on the upper area of personally familiar faces following acquired prosopagnosia. <i>Journal of Neuropsychology</i>, 2, 245-268.</p> <p><i>First eye movement study of PS (prosopagnosia), who was involved in a familiar face recognition task (children of the kindergarten where she works). The results show that she focuses most of the time on the mouth (60%). More strikingly, she fixates exactly on each facial feature (mouth, left eye, right eye) while a normal observer who is familiar with the faces fixates in between features, in the centre of the face below the eyes during face identification (“center of mass” of the individual face).</i></p>
9	<p>Steeves, J., Dricot, L., Goltz, H., Sorger, B., Peters, J., Milner, D., Goodale, M.-A., Goebel, R., Rossion, B. (2009). Abnormal face identity coding in the middle fusiform gyrus of two brain-damaged prosopagnosic patients. <i>Neuropsychologia</i>, 47, 2584-2592.</p> <p><i>Cases PS (prosopagnosia) and DF (aperceptive visual agnosia) : absence of release from adaptation in the FFA of the patients for different faces. Presence of release from adaptation for nonface objects for patient PS but not DF. Shed light on the neural circuitry subtending face and object recognition.</i></p>
10	<p>Ramon, M., Busigny, T., Rossion, B. (2010). Impaired holistic processing of unfamiliar individual faces in acquired prosopagnosia. <i>Neuropsychologia</i>, 48, 933-944.</p> <p><i>Patient PS, tested in 5 experiments showing a lack of whole-part and composite face effects when individualizing faces. The study also shows that there is – unfortunately - a large degree of interindividual variability in the magnitude (and presence) of such effects in a single experiment so that it is difficult to make strong conclusions from the absence of the effect in prosopagnosia based on a single experiment. Yet, the last experiment of the paper relies on a more sensitive composite paradigm and shows a clear absence of holistic processing for the patient PS.</i></p>

11	<p>Ramon, M., Rossion, B. (2010). Impaired processing of relative distances between features and of the eye region in acquired prosopagnosia—two sides of the same holistic coin? <i>Cortex</i>, 46, 374-389.</p> <p><i>Patient PS, tested in an experiment in which various aspects of individual faces were diagnostic for individualization (mouth, eyes, relative distances between features, ...). The patient did not show the same profile of performance as normal observers in normal circumstances, being relatively more impaired at processing the eyes and relative distances. However, when the advantage provided by holistic processing was reduced by indicating the nature and location of the diagnostic cues, the patient's <u>profile</u> of performance looked like normal observers. This study suggests that holistic processing is the cause of the increased difficulties at extracting certain cues (eyes, relative distances) on faces.</i></p>
12	<p>Busigny, T. & Rossion, B. (2010). Acquired prosopagnosia abolishes the face inversion effect. <i>Cortex</i>, 46, 965-981.</p> <p><i>Patient PS, tested with 5 tasks showing a lack of inversion effect: performance is not better or faster for upright than inverted face in the Benton test, delayed and simultaneous matching tasks, and familiarity decisions. No advantage for inverted faces is found for the patient though. A review of the literature shows that cases of inversion superiority in prosopagnosia are very rare and can probably be accounted for by low-level visual defects.</i></p>
13	<p>Busigny, T., Graf, M., Mayer, E., Rossion, B. (2010). Acquired prosopagnosia as a face-specific disorder: Ruling out the general visual similarity account. <i>Neuropsychologia</i>, 48, 2051-2067.</p> <p><i>Patient PS, pure prosopagnosia. Demonstration that her ability to discriminate highly similar visual items is as good as normal observers, with simple shapes and common objects. The still popular view that prosopagnosia can be accounted for by the fact that faces form a particularly visually homogenous category does not hold.</i></p>
14	<p>Van Belle, G., de Graef, P., Verfaillie, K., Busigny, T., Rossion, B. (2010). Whole not hole: expert face recognition requires holistic perception. <i>Neuropsychologia</i>, 48, 2609-2620.</p> <p><i>The first study to use gaze-contingency in a face perception task, performed here in normal observers and prosopagnosic patient PS. The results show a striking dissociation between a condition in which only one fixated feature is revealed at a time (window: relatively less impairment for the prosopagnosic patient than normal observers) and a condition in which the fixated feature is masked (mask: much larger impairment for the prosopagnosic patient).</i></p>
15	<p>Busigny, T., Joubert, S., Felician, O., Ceccaldi, M., Rossion, B. (2010). Holistic perception of the individual face is specific and necessary: evidence from an extensive case study of acquired prosopagnosia. <i>Neuropsychologia</i>, 48, 4057-4092.</p> <p><i>First report of the case of prosopagnosia GG (right unilateral damage, stroke), showing that his impairment is restricted to faces and concerns the ability to individualize faces based on a holistic representation. Extensive investigation (24 behavioral experiments).</i></p>

16	<p>Rossion, B., Dricot, L., Goebel, R., Busigny, T. (2011). Holistic face categorization in higher-level cortical visual areas of the normal and prosopagnosic brain: towards a non-hierarchical view of face perception. <i>Frontiers in Human Neuroscience</i>, 4:225. doi: 10.3389/fnhum.2010.00225.</p> <p><i>Patient PS, pure prosopagnosia. This paper reports (1) a full behavioral study in which we show that she categorizes Mooney and Arcimboldo as faces just like normal observers; (2) an fMRI study in normal participants in which it is shown that contrary to full face photographs, such face stimuli activate the FFA without leading to face-sensitive responses in the inferior occipital cortex (no OFA). (3) This is completed by the same neuroimaging study of PS, showing that she recruits the middle fusiform gyrus (FFA) to perceive these stimuli as faces, just like normal observers. Overall, these observations support the view that face-related activation may emerge in the middle fusiform gyrus independently of any face-sensitive activation in the posteriorly located inferior occipital cortex, especially if the whole configuration of the stimulus is critical for the stimulus to be seen as a face.</i></p>
17	<p>Busigny, T. & Rossion, B. (2011). Holistic processing impairment can be restricted to faces in acquired prosopagnosia: Evidence from the global/local Navon effect. <i>Journal of Neuropsychology</i>, 5-11-14.</p> <p><i>Patient PS, pure prosopagnosia. Demonstration of a normal Navon effect with hierarchical letters, while this case of prosopagnosia has been shown to be impaired at holistic processing of individual faces. This study shows that impairment in holistic face processing is not just an impairment at general holistic processing.</i></p>
18	<p>Van Belle, G., Busigny, T., Lefèvre, P., Joubert, S., Felician, O., Gentile, F., Rossion, B. (2011). Impairment of holistic face perception following right occipito-temporal damage in prosopagnosia: converging evidence from gaze-contingency. <i>Neuropsychologia</i>, 49, 3145-3150.</p> <p><i>In this paper, we show that the pure case of prosopagnosia GG, who has unilateral right hemispheric damage (lingual, parahippocampal and medial part of the fusiform gyrus) also presents with a relatively larger impairment in recognizing faces when preventing him from seeing the central feature of the face (contingent mask) than when restricting his perception to one feature at a time (contingent-window). This is the same pattern of performance as patient PS (Van Belle et al., 2010, paper below), despite almost no overlap between their brain damage.</i></p>
19	<p>Alonso-Prieto, E., Caharel, S., Henson, R.N., Rossion, B. (2011). Early (N170/M170) face-sensitivity despite right lateral occipital brain damage in acquired prosopagnosia. <i>Frontiers in Human Neuroscience</i>.</p> <p><i>The first report of a face-sensitive N170 effect over the right hemisphere of the prosopagnosic patient PS, despite extensive damage in this hemisphere and no evidence of right OFA activation in numerous previous studies. The N170 also shows the amplitude increase and delay to inverted faces. A M170 is also disclosed in a MEG study. Interestingly, the component is absent in the left hemisphere, where she has another lesion in the middle fusiform gyrus (no left FFA). This observation suggests that the OFA is not necessary to observe early sensitivity to faces in the right occipito-temporal cortex.</i></p>
20	<p>Jonas, J., Descoins, M., Koessler, L., Colnat-Coulbois, S., Sauvee, M., Guye, M., Vignal, J-P.,</p>

	Vespignani, H., Rossion, B., Maillard, L. (2012). Focal electrical intracerebral stimulation of a face-sensitive area causes transient prosopagnosia. <i>Neuroscience</i> , 222, 281-288.
21	Busigny, T., Van Belle, G., Jemel, B., Hosein, A., Joubert, S., Rossion, B. (2014). Face-specific impairment in holistic perception following focal lesion of the right anterior temporal lobe. <i>Neuropsychologia</i> , 56, 312-333.
22	Jonas, J., Rossion, B., Krieg, J., Koessler, L., Colnat-Coulbois, S., Maillard, L., Frismand, S., Colnat-Coulbois, S., Vignal, J.-P., Vespignani, H., Jacques, C., Brissart, H., Maillard, L. (2014). Intracerebral electrical stimulation of a face-selective area in the right inferior occipital cortex impairs individual face discrimination. <i>NeuroImage</i> , 99, 487-497.
23	Rossion, B. (2014). Understanding face perception by means of prosopagnosia and neuroimaging. <i>Frontiers in Bioscience (Elite Ed.)</i> ; 6-308-317.
25	Van Belle, G., Lefevre, P., & Rossion, B. (2015). Face inversion and acquired prosopagnosia reduce the size of the perceptual field of view. <i>Cognition</i> , 136, 403-408.
26	Jonas, J., Rossion, B., Brissart, H., Frismand, S., Jacques, C., Hossu, G., Colnat-Coulbois, S., Vespignani, Vignal, Maillard, L. (in press). Beyond the core face-processing network: intracerebral stimulation of a face-selective area in the right anterior fusiform gyrus elicits transient prosopagnosia. <i>Cortex</i> , in press.